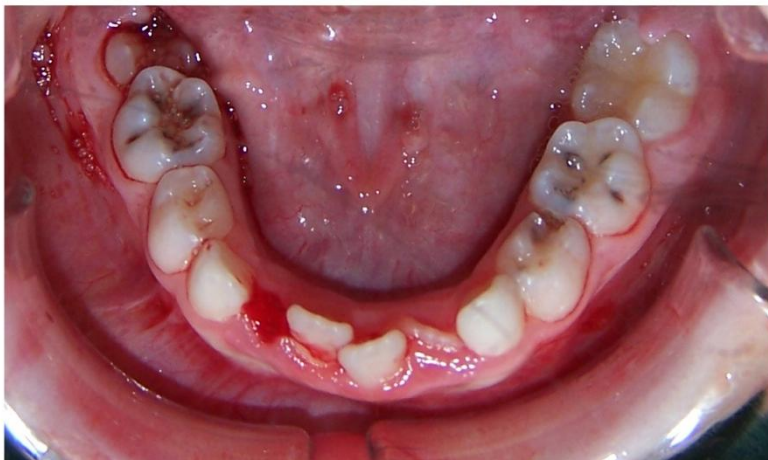
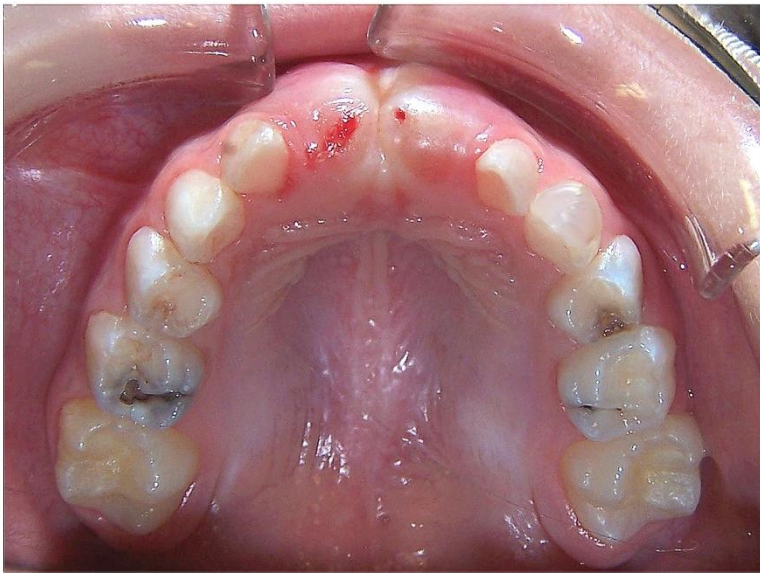

Case 3

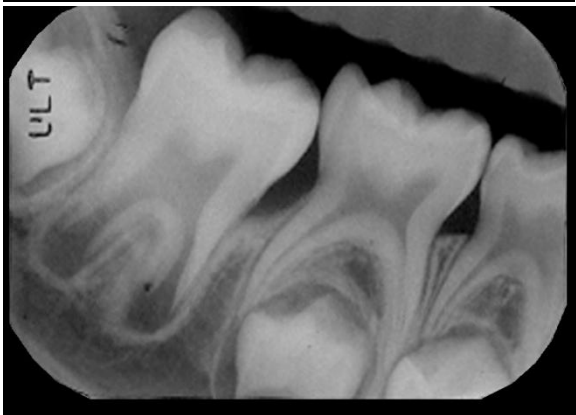
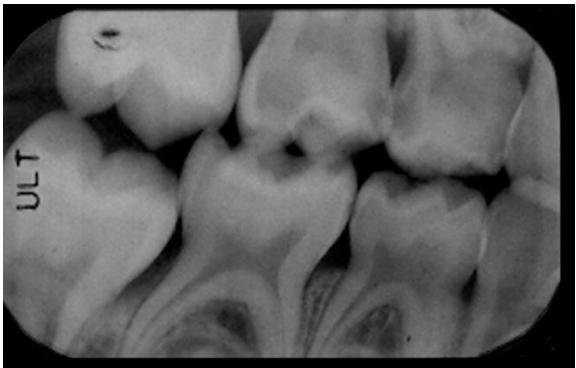
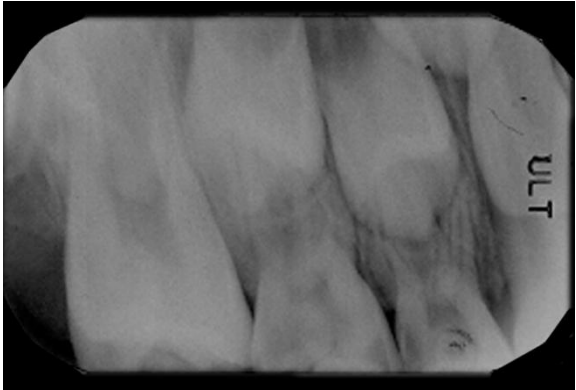
- A- Fill in the dental chart
- B- Identify the dental age and stage
- C- What is the dental diagnosis?
- D- What are the needed radiographs?
- E- Do you need to investigate the un-erupted maxillary central incisors?



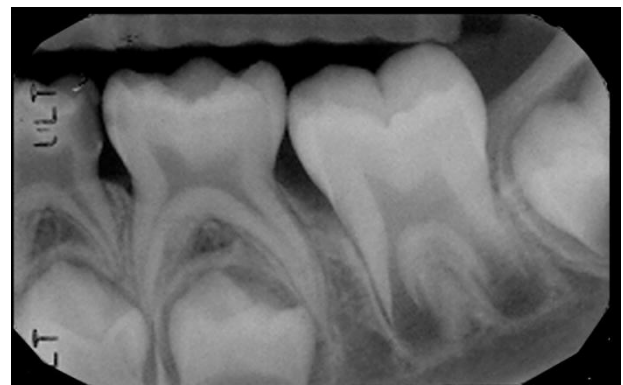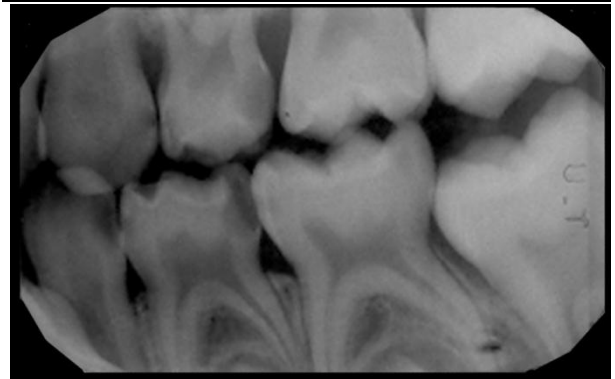
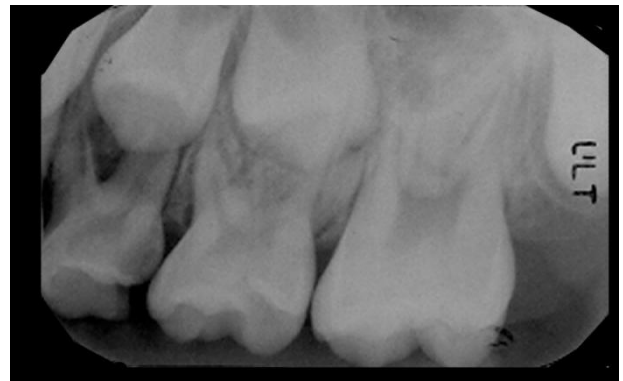RIGHT

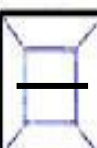


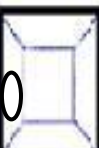






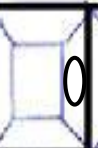



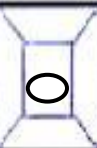






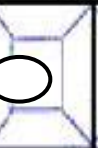
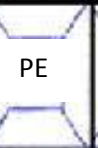
LEFT

What is your treatment plan for the upper and lower right quadrants based on the given chart and radiographs?



What is your treatment plan for the upper and lower left quadrants based on the given chart and radiographs?



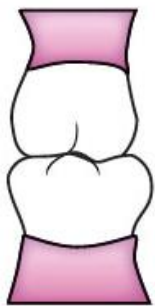| | | | | | | | | | | | | | | | |
|-----------------------|--|---|---|---|---|---|---|---|---|---|---|---|---|------------------|----|
| R I G H T |  |  |  |  |  |  |  |  |  |  |  |  |  | L E F T | |
| | 17 | 16 | 55 | 54 | 53 | 52 | 11 | 21 | 62 | 63 | 64 | 65 | 26 | | 27 |
| |  | PE |  |  |  |  |  | PE |  |  |  | PE |  | | |
| | 47 | 46 | 85 | 84 | 83 | 42 | 41 | 31 | 32 | 73 | 74 | 75 | 36 | | 37 |

Case 3

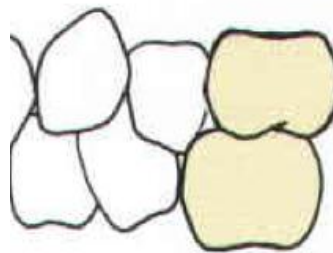
Layla attended your clinic with her grandmother. She was born in October 2009. She complained of pain in the upper left quadrant mainly on eating. She also fell down last week but nothing happened to her teeth

The child was born with a hearing problem which was diagnosed and corrected late. This resulted in significant speech and language delay. She has been to the dentist once before who prescribed an antibiotic for an intraoral swelling. She brushes her teeth occasionally and has seen and detected plaque on most of her teeth. She had more than 5 sugar containing snacks daily. Extraorally she had a bruise in the chin area. Intraorally she had a soft fluctuant swelling on the lower lip. The molar relationship on the right and left sides are as shown in the pictures given.

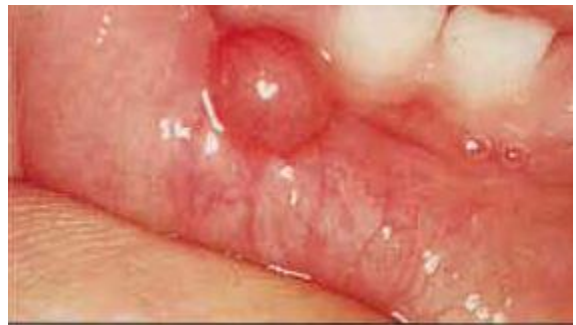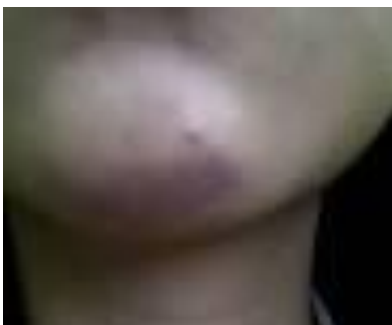- A- Fill the history and examination sheet
- B- The patient attended with her grandmother, what implications does that have?
- C- How would you gain a thorough history about the traumatic episode?
- D- Would you be concerned about the extraoral bruise?
- E- What is the most likely soft tissue diagnosis?
- F- How would you communicate with this child? Any modifications of behavioral management techniques?



Mesial



Mesial



1. Would you place a space maintainer after extraction of 64 and what type?
2. If 54 needed an extraction as well would you change the type of space maintainer needed?
3. What technique of L.A would you use for extracting 64?
4. To do a pulpotomy on 74, what technique of L.A would you use and why?
5. If 85 needed a pulpotomy what technique of L.A would you use and why?
6. How many 2% Articaine carpules can you give this patient given that his weight is 22 Kg?