

# Interim and temporary restoration of teeth during endodontic treatment

A-L Jensen,\* PV Abbott,\* J Castro Salgado\*

## Abstract

One of the main aims of endodontic treatment is to eliminate micro-organisms from within the root canal system. A further aim is to prevent the ingress of any further bacteria during and after treatment. These aims are usually achieved by various means and stages throughout the treatment process. Endodontic treatment is usually performed on teeth that have lost the integrity of the external coronal tooth structure which has allowed bacteria to enter the tooth and ultimately reach the pulp space. Further opening of the tooth occurs when an endodontic access cavity is made to allow treatment to be performed. Hence, there will always be a need for interim and temporary restoration of teeth undergoing endodontic treatment. Many different materials and techniques have been proposed, and these proposals have been based on many research reports. The purposes of this article are to review the literature regarding the use of interim and temporary restorations, and to provide recommendations regarding such restorations for clinicians to follow when providing endodontic treatment.

**Key words:** Temporary restorations, endodontics, bacteria.

## INTRODUCTION

The classic studies by Kakehashi *et al.*,<sup>1</sup> Möller,<sup>2</sup> Sundqvist<sup>3</sup> and others<sup>4-6</sup> have clearly established that most pulp and periapical diseases are a result of the presence of bacteria within the tooth, and particularly within the root canal system. Therefore the main principles of endodontic treatment should be aimed at eliminating all bacteria from the tooth, and then attempting to maintain the tooth in this disinfected state by preventing any further ingress of bacteria during and after treatment. If this can be achieved, then the tooth should be able to be retained in the mouth and can be returned to its normal functional and aesthetic state.

The microbial flora within a tooth and its root canal system can be eliminated through a combination of the following eight steps that form part of the typical endodontic treatment regime adopted by most dentists:

- (1) Diagnose and remove the cause of the disease(s).
- (2) Use an aseptic technique (which includes the use of rubber dam).
- (3) Mechanically instrument the root canals to enlarge them.
- (4) Irrigate the canals with one or more antibacterial solutions.
- (5) Medicate the canals with one or more antibacterial agents.
- (6) Temporarily restore the tooth to avoid bacterial ingress during and after treatment.
- (7) Fill the root canal system once disinfected.
- (8) Restore the tooth to normal function.

If one or more of the above steps are not incorporated into the treatment regime, then there is potential for either the bacteria that are already in the tooth to survive and proliferate, or for new organisms to enter the tooth and establish colonies. The eventual result of both of these scenarios is continuation of the apical periodontitis that was already present, or the development of a new apical periodontitis lesion. Hence, in order to predictably achieve favourable healing of the apical periodontium following endodontic treatment, all of the above steps should be incorporated into the treatment regime using established and proven protocols for each stage.

As outlined above, the main cause of pulp and periapical diseases is the presence of bacteria within the tooth. Hence, clinicians must determine how the bacteria entered the tooth in order to remove the pathway of entry and prevent further bacterial ingress. The most common pathways for bacterial penetration into a tooth are via caries, cracks, exposed dentine and broken down restoration margins.<sup>9-13</sup> Hence, an integral part of endodontic treatment is to remove these pathways from the tooth prior to commencing the bio-mechanical management of the root canals. This implies that all existing restoration(s) must be removed, along with any caries and cracks in the tooth, as these are all potential pathways for re-infection of the tooth during and/or after the endodontic treatment.<sup>14</sup> It has been shown that the typical clinical and radiographic examinations that are carried out by dentists and endodontists prior to endodontic treatment do not indicate with any degree of certainty if there are caries,

\*School of Dentistry, The University of Western Australia.

cracks or signs of marginal breakdown of a restoration in a restored tooth that has pulp and/or periapical disease.<sup>14</sup> In addition, these examinations do not show the full extent of such problems or whether there is sufficient tooth structure remaining to enable adequate restoration of the tooth following endodontic treatment.<sup>14</sup> Removal of all restorations, caries and cracks can be called "investigation" of the tooth and it is during this phase of treatment that the long-term prognosis and the future restorative treatment needs of the tooth can be assessed.

If the above principle of removing all restorations, caries and cracks is followed, then it will be necessary to consider how to restore the tooth in an interim manner whilst the endodontic treatment is carried out since endodontic treatment is usually completed over multiple appointments.<sup>15,16</sup> Such an approach allows the use of intracanal medication(s),<sup>17,18</sup> which increases the rate of favourable outcomes,<sup>15,19</sup> reduces bacterial numbers more predictably,<sup>20,22</sup> improves operator time management,<sup>15</sup> increases patient comfort and decreases operator stress and fatigue.<sup>23,24</sup> However, some dentists may choose to complete the endodontic treatment in one session but this implies that medicaments cannot be used – hence, one of the above eight steps cannot be incorporated and this can reduce the predictability of the treatment outcome. In such cases, an interim restoration of the tooth will still be required unless the definitive coronal restoration of the tooth is also done at that same appointment.

When a multiple appointment approach has been adopted, an "ideal" or "textbook" access cavity can be cut through the interim restoration at the second and subsequent appointments. The biomechanical preparation and filling of the root canal(s) can then be performed through this access opening. At the conclusion of the second and any subsequent appointment(s), this access cavity will need to be temporarily filled. This is often done with a different restorative dental material to that used for the interim restoration and some operators will use two layers with different materials.

Currently in many dental practices, the definitive coronal restoration is not placed at the same appointment as when the root filling is placed. In most regions where a specialist endodontist has done the endodontic treatment, the specialist does not place the definitive coronal restoration and the referring general dentist will complete this component of the treatment at a later appointment. Thus, the combination of an interim restoration with a temporary access cavity restoration may remain in place for variable periods of time. Consequently, it is essential that the interim restoration is not compromised by the cutting of the access cavity through it and that the materials used will prevent bacterial penetration into the tooth despite having two interfaces and being subjected to moderate masticatory load for variable periods of time. This will help to more predictably achieve a bacteria-free environment within the root canal system and it will also help to sustain such an environment.

Siren *et al.*<sup>25</sup> reported that "if the root canals had been unsealed at some point during the treatment, enteric bacteria were found more frequently than in canals with an adequate seal between the appointments". This finding implies a decreased prospect of a favourable long-term treatment outcome if the interim or temporary restorations are inadequate or breakdown at any time during the treatment process.

## TERMINOLOGY

In any scientific discussion, it is important to define the terms being used since terminology can vary between authors and it can be ambiguous. In many instances "popular" terminology is used by the profession even though it may not be accurate or appropriate. Hence, the terms used in this review are defined below.

### Interim restoration

This term is used to describe a restoration that has been placed in a tooth after the previous restoration, cracks and/or caries have all been removed at the commencement of endodontic treatment (i.e., the "investigation" stage of treatment). Such a restoration will remain in place whilst the endodontic treatment is being performed and after the root canal filling has been completed until the definitive coronal restoration is placed.

### Temporary restoration

This term is used to describe a restoration placed within an endodontic access cavity; such a cavity is likely to have been cut through an interim restoration in most cases if the above treatment approach is followed. These aforementioned terms are appropriate because of the connotation that "temporary" suggests a shorter time than "interim". The purpose of each is different to the other, and different materials and techniques are likely to be used – therefore different terms should be used. The cavity designs and requirements will also be markedly different: for interim restorations, these will be determined by the extent of the previous restorations, caries and cracks whilst the anatomy of the pulp chamber and root canals will determine the extent of the access cavity and thus the temporary restoration.

### Leakage and microleakage

"Leakage" is defined as "the action of leaking, admission or escape of water or other fluid through a hole in a vessel, or loss of fluid by this means".<sup>26</sup> The addition of the prefix "micro" suggests that such leakage is microscopic in amount or is measured in units one millionth (i.e.,  $\times 10^{-6}$ ) that used for "leakage". Brannström<sup>27,28</sup> and colleagues were probably the first to publish articles using these terms when they proposed that infection caused by the penetration of micro-organisms into the tooth via the margins of a restoration was a greater threat to the pulp than the

toxicity of the restorative material itself. Consideration of the above definition indicates that these terms are quite inappropriate for use in dentistry and, although in popular use for many years, their use should be discontinued. The above definition does not accurately represent the clinical situation for any dental restoration (whether it be a definitive, provisional, interim or temporary restoration) or for a root canal filling as technically there is no escape of fluid out of the tooth or root canal system. There may be some admission of saliva into the tooth but the key problem that should be considered is whether *bacteria* can enter the tooth system. Hence, a more appropriate term to use instead of "leakage" is "bacterial penetration". The term "penetration" is more accurate as it communicates that there is *ingress* of substances rather than an *egress*.

### Seal

A "seal" is defined as something that blocks entry into or out of a container or other object.<sup>26</sup> Hence, it is a difficult term to justify or use clinically since complete sealing of a tooth is impossible with currently available dental materials and due to the porous nature of the tooth structure itself (especially dentine, but also enamel). Clinically, the ingress or penetration of bacteria or toxins beneath a restoration cannot be visualized or assessed whilst the restoration is in place unless there has been gross breakdown or the development of obvious dental caries. Therefore, clinicians should be very wary of, and refrain from, describing a restoration as "sealing the tooth". Instead, the margins of restorations should be described as being clinically or radiographically satisfactory or unsatisfactory as these terms are more appropriate and scientifically more accurate.

### Restoration breakdown

This term is used to describe a restoration that has clinical, radiographic or other signs of loss of the integrity of its margins – i.e., breakdown. This term is proposed as an alternative to the currently popular terms such as ditching, failing or leaking. Terms such as "failing" imply to both the patient and clinician that the restoration was of poor technical quality from the outset. This portrays the practitioner who placed the restoration in a negative way when the restoration may have been successful and functioning for many years before breaking down and allowing new bacteria to enter the tooth system. This is not a true "failure" of the restoration although it could be considered as a failure of the material to last the patient's lifetime – but this is an unrealistic expectation in a biological environment that has many factors that can lead to breakdown of a foreign material.

### LITERATURE REVIEW

Except for the recent article by Abbott<sup>14</sup> and a recommendation by Melton *et al.*<sup>29</sup> there is a paucity of literature regarding the removal of restorations prior to

the commencement of endodontic treatment. Both clinicians and researchers alike acknowledge that bacteria are the primary cause of endodontic disease. Furthermore, it is accepted that anachoresis is an uncommon event<sup>30</sup> and thus it can only be concluded that pulp disease is chiefly due to bacterial ingress from the oral environment into the coronal aspect of the tooth. It is recognized that radiographs and clinical examination alone cannot, with any adequate specificity and sensitivity, reveal caries,<sup>31</sup> cracks<sup>32,33</sup> and previous pulp exposures<sup>34</sup> underneath existing restorations. Abbott<sup>14</sup> reported that there is only a 56 per cent chance of detecting caries, cracks or marginal breakdown in restored teeth with pulp and periapical disease when routine clinical and radiographic (periapical) examinations are performed. Such a low level of detection is unreliable. Abbott<sup>14</sup> also found that 95 per cent of the teeth examined in his study had more than one of the aforementioned factors that could have contributed to the development of pulp and periapical diseases. In contrast, most endodontic textbooks suggest that, in theory, it is "preferable to remove restorations . . . but this is often neither feasible nor desirable".<sup>35</sup> These texts do not recommend removal of the existing restoration(s) in any of the clinical stages of treatment nor do they explain why removal is often neither feasible nor desirable. However, this approach ignores the cause of the diseases and is likely to lead to unfavourable treatment outcomes since the cause is not removed as part of the treatment process.

A review of the literature examining fluid penetration of indirect restorations compared to direct restorations demonstrates, when examined quantitatively, that indirect restorations have slightly less penetration than direct restorations,<sup>36</sup> but this was often not significant.<sup>37</sup> The majority of these studies also demonstrate that there is evidence of fluid penetration regardless of whether the restoration is direct or indirect.<sup>36,37</sup> Goldman *et al.*<sup>38</sup> examined different types of crown margins and the impact this had on dye penetration under thermocycling and they concluded that "all crowns demonstrated significant leakage following the path of dentine tubules to the pulp". Furthermore Goldman *et al.* stated that "this could possibly be one of the causes of pulp inflammation and even pulp death under full crowns".

Turner *et al.*<sup>39</sup> carried out a fluid filtration study of temporary restorations in endodontic access cavities that had been cut through existing restorations. The conclusion was that the fluid penetration of the access cavity temporary restoration could not be fully assessed due to the fluid also penetrating through the existing restoration. In a similar study, Melton *et al.*<sup>29</sup> also concluded that there was significant dye penetration around the permanent restoration-tooth interface. These studies suggest that any clinical attempt to disinfect the root canal system in these circumstances is being negated by the inadequacies of the existing restoration.

In the study discussed above by Abbott,<sup>14</sup> caries was found in 86 per cent of the teeth with direct restorations and in 81 per cent of teeth with indirect restorations (crowns) once the existing restorations had been removed. These findings suggest that there is a similar incidence of caries under crowns or indirect restorations as there is with direct restorations when the teeth have pulp and periapical disease, but clinically it was often more difficult to detect the caries under crowns before the restorations were removed. Therefore the removal of all coronal restorations (both direct and indirect) prior to the commencement of endodontic treatment should be mandatory.

Contrary to the above, coronal restoration of the endodontically treated tooth,<sup>40-43</sup> sometimes referred to as the "extensively broken down tooth",<sup>44</sup> is widely discussed in the literature and there are many treatment modalities for managing these teeth with minimal remaining tooth structure. Smith and Schuman,<sup>41</sup> in discussing the restoration of endodontically treated teeth, state that the first stage is to assess if the tooth is restorable. The practicality of doing this if the endodontic treatment has already been carried out (rather than *prior* to the endodontic treatment) is very questionable since it may lead to the patient incurring considerable cost, discomfort and unnecessary treatment if the tooth is deemed to be not restorable at the definitive restoration stage. Such a retrospective approach may be common within the profession but it does not follow the principles of good or logical treatment planning protocol. McDonald and Setchell<sup>45</sup> have proposed a "restorability index", recognizing the importance of this stage in clinical treatment planning. It was noted that the amount of dentine and the strategic value of the remaining tooth structure was of importance. The only way the clinician can accurately assess whether the tooth is suitable for restoration (and therefore endodontic management) and give an informed opinion on the prognosis<sup>46</sup> prior to treatment is to completely remove the existing restoration(s).

As defined above, the interim restoration is placed after the tooth has been investigated during the first appointment for endodontic management. In addition to preventing bacterial ingress, interim restorations used during endodontic treatment must also meet the following three criteria:

- the tooth must be able to continue functioning,
- the operator must have adequate access to the root canal system, and
- the patient must be able to maintain normal oral hygiene measures around the tooth to prevent caries and the retention of plaque and calculus.

Currently there is not one material that fulfils all of these criteria. The extent, size and cavity design of the interim restoration will be determined by the extent of the previous restoration, caries and cracks.

Anusavice<sup>47</sup> has outlined the ideal properties of interim restorations. He states that they must:

- have satisfactory appearance in areas of aesthetic concerns,
- have easily identifiable margins to facilitate removal of the interim restoration after completion of endodontic treatment,
- adhere to tooth structure – thus requiring no additional retention form and thereby indirectly allow conservation of tooth structure,
- be easy to place and handle,
- be cost effective,
- have good tensile strength in minimal thickness and bulk,
- have good dimensional stability when an access cavity is cut through it and not be adversely affected by heat once set (e.g., during obturation of the canal),
- be able to reproduce tooth contours to allow ease of cleaning and maintain space,
- have a moderate degree of moisture tolerance during subgingival marginal placement,
- adhere to stainless steel if a band is being used,
- have a long shelf life, and
- require only minimal tooth preparation prior to placement.

Unfortunately, there is no ideal material available for interim restorations that meets all of these criteria. Materials that are currently used are a compromise in many aspects but the clinical results are still promising. Case reports, such as that by Vail and Guba,<sup>48</sup> demonstrate the role of the interim restoration in eliminating bacterial ingress and thereby changing the microbial niche to allow healing despite not having complete endodontic treatment. These authors reported a case where a patient had emergency endodontic treatment but did not return for further treatment for another two and a half years. The interim restoration was still intact and complete periapical healing was demonstrated by radiographs, despite minimal palliative treatment. A similar case is shown in Fig 1.

Upon considering the purposes, cavity design requirements, ideal properties for interim restorations and the lack of suitable materials to suit all of these needs, it is not surprising that there have been various materials used for interim restorations. Over the years the dental literature broadly discusses "temporary materials" with no apparent definition of the term. Sturdevant *et al.*<sup>49</sup> stated that the selection of a temporary restorative material depends on the extent of the cavity, the anticipated duration for which it will have to last, and the properties required. Commonly used materials within endodontics are: glass ionomer cements (GIC), resin modified GIC, reinforced GIC, composite resins, amalgam, reinforced interim restorative material in a zinc oxide eugenol base (e.g., IRM – Dentsply Caulk, Milford, USA), and a calcium sulphate based filling material (e.g., Cavit – 3M ESPE, Seefeld, Germany). These latter two materials are frequently used as

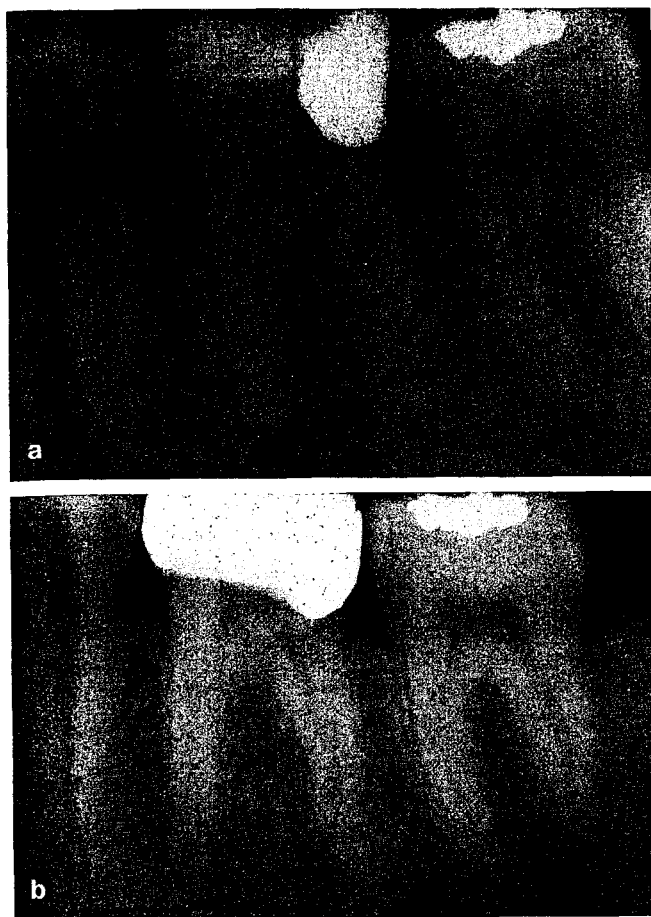


Fig 1. (a) Pre-operative periapical radiograph of the lower left first molar tooth in a patient who presented with a pulpless, infected root canal system and secondary acute apical periodontitis as a result of breakdown of the restorations and the presence of caries.

The restorations and caries were removed and the tooth was deemed to be suitable for further restoration. Endodontic treatment was commenced – the pulp chamber was accessed and the canals were irrigated and lightly instrumented. An intracanal medicament was placed and an interim restoration was placed using a stainless steel band and a silver-reinforced glass ionomer material.

(b) A review periapical radiograph of the same tooth taken when the patient returned for the continuation of treatment after 2½ years. This radiograph shows the interim restoration is still in place. The apical periodontitis associated with the distal root has healed, as evidenced by resolution of the periapical radiolucency that was present on initial presentation for treatment. The mesial periapical radiolucency has considerably reduced in size indicating that the previous apical periodontitis lesion is healing.

temporary restorations either alone or in combination such as when a so-called “double seal”<sup>50</sup> is used – in such cases, Cavit is placed as an underlying material within the pulp chamber and then IRM is placed as the “external” material.<sup>51-53</sup> Some operators may use Cavit in conjunction with a GIC material in a similar manner with the GIC being used as the overlying interim restoration.

The integrity of interim restorations used during endodontic treatment has been assessed with various studies that have principally been designed to attempt to simulate bacterial ingress between the tooth and the restorative material. However, the results have been contradictory, and controversy exists regarding the validity of the various testing methods used.<sup>54-62</sup> Many studies have concentrated on the type of dye or fluid

used and the effect of air entrapped within the canal or the root canal filling regardless of whether coronal or apical “leakage” (i.e., penetration) was being examined. Typically coronal fluid penetration studies have only assessed temporary restorations placed inside endodontic access cavities in extracted teeth. Most of these studies have not had any other form of restoration in the tooth and the ability of comprehensive interim restoration(s) to resist bacterial penetration has not been considered.<sup>53,63-68</sup>

Dye penetration studies are inexpensive and simple to conduct but no correlation has been established between the penetration of dye through restorations and that of bacteria. In addition there are no studies that compare the validity of dye studies to bacterial tracers. Penetration studies, as a group, are based on the assumption that clinically these represent bacterial tracers or toxins. However, at present there is no proof as to whether this assumption is accurate or not and further research is required to ascertain this information. Authors reporting the results of penetration studies should outline in their discussion that there are a number of assumptions throughout the study and these should be clearly stated for the reader.

Bacteria are arguably the most relevant tracers but unfortunately it is not known which particular species or combination of species is the most representative to use in an experimental model. This is due to the limited knowledge of endodontic microflora at various stages of endodontic disease,<sup>69</sup> particularly those that cause the continuation of apical periodontitis during or immediately after endodontic treatment. Researchers have the following additional problems that complicate investigations of this clinical problem:

- the relevant bacteria are difficult to culture,
- anaerobic bacteria are fastidious and difficult to handle, thus complicating the experiment,<sup>70</sup>
- bacterial culturing and identification of the species is expensive, time consuming and requires specialized equipment and knowledge,<sup>69</sup>
- all equipment, materials and teeth used in the model must be sterilised and the procedure conducted under aseptic conditions if a bacterial tracer is to be used,
- it is not known whether it is the bacteria themselves that cause unfavourable endodontic outcomes or whether it is their by-products such as endotoxins, and
- increasingly there is new information showing that bacteria survive in biofilms rather than as pure isolates; consideration must be given to the different gene expression exhibited by bacteria in biofilms than by the same bacteria in planktonic form.<sup>71</sup>

These factors partially contribute to the reasons why there are so few bacterial penetration studies reported in the dental literature. Critics and authors recognize that bacterial penetration through a tooth model does

not allow the conclusion to be drawn that this clinically indicates a particular periapical condition will occur, nor does it indicate the duration of time before clinical disease develops or what quantity of bacteria the host defense system is able to tolerate before disease develops and manifests.

A temporary restoration, as defined above, is the restoration placed within an endodontic access cavity that has been cut through an interim restoration or through tooth structure. Clinically it is rare that a tooth will have no restorations other than the temporary restoration, but this can occur in teeth that have developed pulp and periapical diseases as a result of trauma, dentine exposure, attrition or periodontal disease. The access cavity form will be determined by the overall anatomy of the tooth being treated but to an even greater extent by the anatomy of the root canal system. It will also be influenced by the operator's experience and skill. An inadequate access cavity will complicate treatment due to reduced visualization and access to the canal orifices,<sup>72,73</sup> and therefore it is essential that such cavities are adequate in their size, shape and position.

There have been various studies conducted to test the effects of the thickness of temporary restorations. These studies have usually concentrated on temporary materials<sup>74</sup> such as TERM,<sup>68</sup> IRM and Cavit.<sup>75</sup> These studies have typically investigated what the authors have called "microleakage" although it has usually been fluid penetration that was actually reported. In addition, they usually only involve temporary restorations and not interim restorations, and therefore, they have little clinical relevance. Additionally should a clinician find they have less than the ideal depth of the material present, then there is no accepted method to increase this depth if the size and status of the tooth and/or the inter-occlusal distance between the dental arches does not allow for the "ideal" depth of material to be used.

The temporary restoration differs considerably to the interim restoration in that:

- it is used in a small quantity, thus it needs adequate strength in minimal bulk,
- its strength can be less than the interim material which will support the temporary material,
- it can be a different colour and not necessarily aesthetic, unlike the interim material,
- it requires a greater compressive strength than the interim material but less tensile strength as the load distribution is not the same,
- it needs to adhere to the tooth and/or the interim restoration despite the lack of any apparent retention or resistance form,
- it should be compatible with the interim restorative materials,
- it needs to be easier to handle, quicker to place and remove as it is not anticipated that this should take the clinician as long as placing or removing the interim restoration, and

- it should also be cheaper and cost effective.

In addition to the above, the ideal temporary filling material should:

- not contract when placed,
- have low solubility,
- have good surface hardness,
- be antibacterial,
- be visually apparent so clinicians can tell that treatment is in progress,
- create a margin against the interim restorative material that is impervious to bacteria or their products, and
- be quick setting.

These ideal properties have been included for completeness but no such material is currently available commercially. Clinicians must recognize that the current materials used are a compromise and dental researchers should strive to develop new and improved materials. However, these processes can only commence if there is recognition of what is ideal.

The most common materials used in endodontic access cavities are: Cavit, IRM, GIC and resin modified GIC. These materials are either used alone or in combinations as a "double seal" technique. Many operators use Cavit and IRM or Cavit and a GIC (or a resin modified GIC) when placing a "double seal". There are also reports of some operators using gutta percha as the temporary restoration, but this material has demonstrated significant dye penetration.<sup>68</sup>

Materials science and its details are beyond the scope of this discussion although there are specific material concepts that warrant consideration when examining dye penetration of temporary and interim restorations. The important variables that may impact on this type of study and its outcomes include:

- the different water absorption, expansion and setting reactions of the materials,
- whether the materials are hand mixed, pre-mixed or supplied in capsules,
- the possible interaction between the different materials used.

Kazemi *et al.*<sup>63</sup> carried out an experiment examining the marginal stability and permeability of Cavit, IRM and Tempit. The first part of the experiment was a simple passive dye penetration study with thermocycling whilst, in the second part, the authors attempted to eliminate the possible effects of the hygroscopic setting mechanisms of the materials. Samples were first allowed to set under water before being placed in dye in standardized glass tubes. This study demonstrated that Cavit had a substantial amount of dye diffusion into the body of the material yet this same material exhibited the least overall dye penetration at all times. IRM demonstrated the least body penetration of all three materials but had substantial marginal penetration that was not significantly different from the results of the Tempit material. The setting expansion of Cavit has

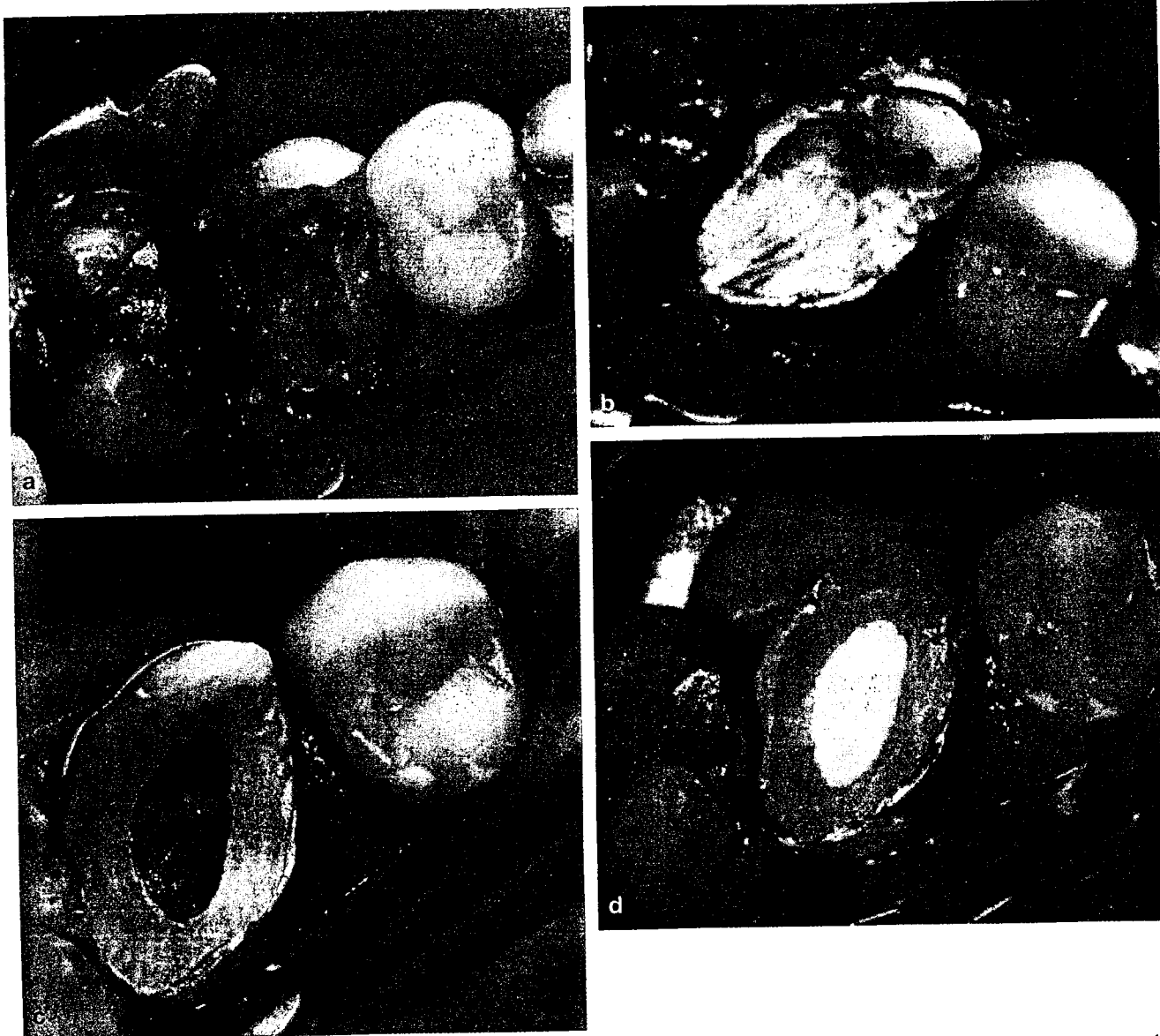


Fig 2. (a) Upper left first molar tooth, isolated with the rubber dam cuff technique, after removal of the previous restoration, caries and cracks as part of the "investigation" of the tooth prior to commencing endodontic treatment. The pulp chamber has been opened and the three canals have been negotiated. The tooth is now ready for the placement of an intracanal medicament and then an interim restoration. (b) An interim restoration has been placed using Ketac Silver and a stainless steel orthodontic band. (c) At a subsequent appointment, the tooth has again been isolated using the rubber dam cuff technique. An access cavity has been cut through the interim restoration so endodontic treatment can be continued. (d) At the end of the appointment, the access cavity has been closed with a temporary restoration using the "double seal" technique by placing cotton wool in the pulp chamber, followed by a layer Cavit and then IRM as the external material.

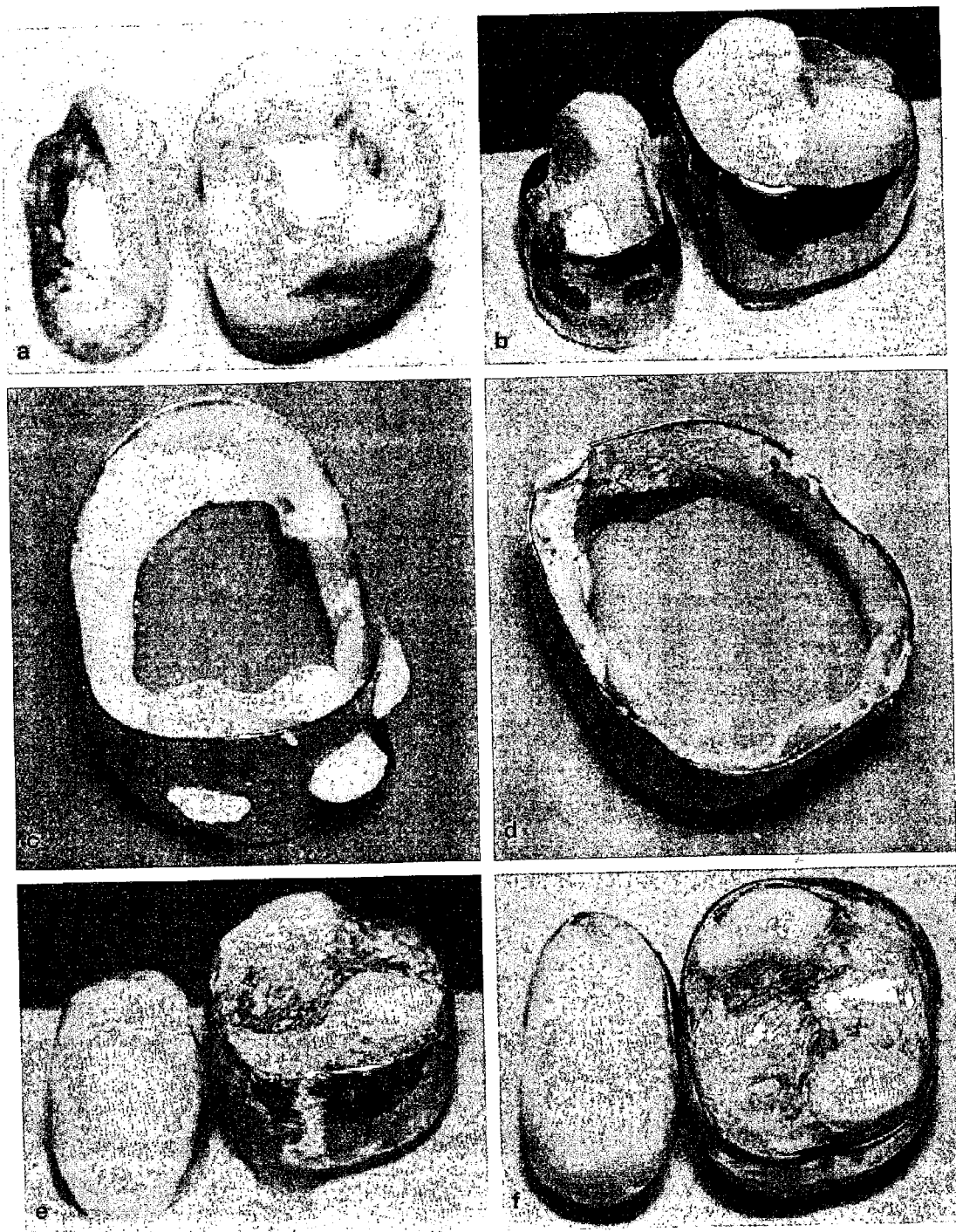
been noted in many dye/fluid penetration studies as the probable reason for its superior performance in such experiments.

The papers by Turner *et al.*<sup>39</sup> and Pai *et al.*<sup>51</sup> are valuable as they considered the placement of both an interim and a temporary restoration. In both papers the specimens were intact, non-carious, non-restored extracted teeth. The teeth then had either Class I occlusal cavities or a standard access cavity cut and restored. The secondary access cavity to the pulp chamber was made through the initial Class I cavities. Anderson *et al.*<sup>76</sup> and Melton *et al.*<sup>29</sup> examined teeth with a history of caries, which required or had multi-surface restorations reflecting common clinical practice. Anderson's group placed extensive restorations and

compared different interim materials using the fluid filtration model, whilst Melton's group cut access cavities through coronal restorations that were already present. Melton and colleagues reported that "a great deal" of dye penetration was observed around the permanent restoration-tooth interface and they recommended the removal and replacement of the coronal restoration prior to endodontic treatment.

Other materials have been reported as being used as endodontic temporary and interim restorations. Ehrmann<sup>77</sup> was the first to suggest the use of stainless steel orthodontic bands during the endodontic treatment of posterior teeth in 1968. Later Ehrmann and Tyas<sup>78</sup> published a paper discussing the cementation of stainless steel bands around cracked teeth to alleviate





**Fig 3.** This *in vitro* model shows the technique for placing interim restorations on a molar and a premolar tooth using stainless steel bands and glass ionomer materials. (a) The teeth have been "investigated" by removing all the previous restorations, caries and cracks to determine whether endodontic treatment and further restoration are feasible and whether the prognosis is suitable. The pulp chambers have been accessed and the root canals have been negotiated. An intracanal medicament has been placed in each canal, and then some cotton wool was placed into each pulp chamber. A layer of Cavit has then been placed over the pulp chamber to prevent the interim material from going into the canals and to allow easy access into the pulp chamber and canals at subsequent appointments. (b) Stainless steel bands are being tested for size and fit prior to cementation. Note that the premolar band has had two holes cut through the buccal aspect of the band – these holes will help to retain the GIC veneer that will be placed over the buccal of the band in order to provide an aesthetic interim restoration on this tooth. (c) The inner/fitting surface of the premolar band has been coated with Ketac Fil prior to seating the band on the tooth. Note how some of the material has extruded through the retention holes on the buccal aspect of the band. (d) The inner/fitting surface of the molar band has been coated with Ketac Silver prior to seating the band on the tooth. (e) After seating the bands on the teeth with their respective GIC material acting as a cement, more of the same material is added to each cavity in order to completely fill them. The material should be flowed into place and then coated with Ketac Glaze or other similar resin bonding agent to prevent moisture loss and/or contamination whilst the material sets. This resin can be placed using a cotton pellet and tweezers to coat the GIC and whilst doing so, a smooth surface can be created so only minimal finishing is required once the material sets hard. This photograph shows both teeth with their completed interim restorations after final smoothing and polishing. Note in particular how the buccal cusp of the premolar has been restored to provide an aesthetic interim restoration. (f) An occlusal view of the finished interim restorations.



symptoms and to facilitate endodontic diagnosis which was, and still remains, a widely accepted management technique.<sup>72</sup> Abbott<sup>80</sup> has continued to teach the concept that stainless steel bands can be used in conjunction with the placement of interim restorations in teeth with large cavities when there are missing cusps (Figs 2 and 3) and when cusps were susceptible to fracture during the course of endodontic treatment.<sup>80</sup> The main purpose of the band is to help retain and strengthen the interim restoration, particularly when an access cavity is subsequently cut through it (Fig 2).

Although the use of bands is logical and clinically applicable, there is currently little scientific evidence to support it. Pane *et al.*<sup>81</sup> carried out a radiographic study and they expressed concerns that the marginal adaptation of stainless steel bands used during endodontic treatment may produce gingival irritation. Clinically this may not be relevant due to the short term use of these bands and especially if the patient undertakes adequate oral hygiene measures. In addition, this is much less concerning if the endodontic treatment is to be followed by crown lengthening surgery. The relevance of the concerns of Pane *et al.* should also be considered in light of the use of full fixed orthodontic appliances that often remain *in situ* on multiple teeth for approximately 2–3 years<sup>82</sup> and sometimes even longer. However, there are no long-term studies involving the use of stainless steel bands during endodontic treatment in adult patients and the impact this has on the periodontal tissues.

Pane *et al.*<sup>81</sup> also examined the effect of stainless steel bands on cusp flexure of maxillary premolar teeth. They concluded that stainless steel bands used during endodontic treatment decreased cusp flexure by half and increased tooth fracture resistance when the tooth was placed under load. This is a useful finding as most teeth that require endodontic treatment are extensively broken down<sup>83</sup> and some cases may already have complex interim restoration(s) placed. The existing restoration will generally have marginal breakdown, and could fracture or dislodge once the access cavity has been cut through it, or the cusps may be undermined and weakened.

Anderson *et al.*<sup>76</sup> examined teeth with multi-surface cavity preparations that were restored with Cavit, IRM or TERM (i.e., as extensive interim restorations) using a fluid filtration technique after thermal stress. TERM demonstrated statistically significantly less fluid penetration than the other materials used and Cavit was deemed to be clinically unacceptable. This is one of the few papers published that discusses multi-surface interim restorations, but unfortunately Anderson and colleagues<sup>76</sup> did not load the teeth and did not cut an access cavity back through the interim restorations to see if this affected the outcome. Their choice of materials for such large cavities probably affected the results and therefore this study cannot be reliably used to indicate how these materials would perform as temporary restorations in access cavities.

Pai *et al.*<sup>51</sup> examined the interfaces of temporary restorations with the cavity walls, the existing coronal restoration into which the access cavity had been cut and the new temporary restoration. Unfortunately, the teeth in this study were only thermocycled and they were not mechanically loaded. In addition the authors did not clearly outline the extent of the cavity so the results cannot be relied upon as an indication of clinical performance.

The literature contains various papers that have examined:

- temporary restorations in teeth with only an access cavity<sup>52,63,65,67,84-93</sup>
  - with thermocycling<sup>52,63,67,90,91,93</sup>
  - with loading<sup>92</sup>
  - with thermocycling and mechanical loading,<sup>84</sup>
- extensive interim restorations after thermal stress,<sup>76</sup>
- extensive interim restorations with access cavities but no loading or thermocycling,<sup>29</sup>
- moderate interim restorations with access cavity, thermocycling and the different interfaces between the materials, and<sup>14,51</sup>
- access cavities cut through 'permanent' restorations.<sup>39</sup>

Despite the large number of studies that have been carried out, none have examined the integrity of interim restorations after cyclic loading. Likewise, none have examined the effects of cyclic mechanical loading of interim restorations with endodontic access cavities cut through them. It is anticipated that loading of such restorations will have an impact because of the multi-surface cavity and the multiple interfaces of the restorations combined with the cusp deflection under loading. In addition, if the tooth and restorations are submersed in the dye or tracer solution during the simulated chewing/loading, then there may be an increase in penetration through the margins due to the factors discussed above and the resultant "pumping" action at the interfaces. Hakimeh *et al.*<sup>94</sup> studied the effect of load cycling, thermal cycling and cavity shape differences on the dye penetration of Class V compomers to determine the significance of each factor but no such research has been published in relation to endodontic access cavities, temporary and interim restorations.

Normal masticatory load or function is difficult to replicate and the need to load teeth when carrying out fluid or bacterial penetration studies is usually overlooked. This was noted by Liberman *et al.*<sup>92</sup> who reported significantly more radioactive dye penetration when temporary fillings in endodontic access cavities had been loaded compared with the same materials when they had not been loaded. Furthermore, they also commented that the testing of restorative dental materials for fluid penetration with no reference to masticatory forces is of limited value. They tested IRM and a calcium-sulphate material firstly without loading and their results showed that "the two materials

provided a similar quality of seal". The same materials were then loaded with 4kg applied repetitively from the occlusal aspect. The IRM maintained a reasonable seal after loading but the calcium-sulphate material deteriorated very rapidly once loaded and was reported to perform similarly to a cavity that had no restoration at all. In this study, the specimens were only exposed to a single directional force hitting the tooth or restoration repetitively rather than having a load that simulated masticatory function. *In vivo* mastication involves forces with infinite force vectors and loading that may be on the tooth, restoration, margin or all of the above at any one stage in the masticatory cycle.

Mayer and Eickholz<sup>84</sup> applied both thermocycling and mechanical loading to teeth with a conservative access cavity preparation and a temporary restoration. Although they concluded that the loading did not influence the fluid penetration as significantly as the thermocycling, they did state that loading of the temporary restoration resulted in a significant reduction in the marginal quality of the restoration. Since the restorations were only loaded 200 times, it is possible this was insufficient load to result in complete marginal breakdown. Perhaps if the loading time had been extended, as would occur clinically, there may have been an increase in dye penetration that would accompany the marginal breakdown. The authors suggested that the lack of increased dye penetration in the loading part of the experiment may have been because "almost all fillings showed dye penetration into the endodontic cavity after thermocycling already. The differentiation between the two dyes was difficult".

Neither of the two aforementioned studies utilized a natural tooth antagonist against the experimental tooth and restoration. Krejci *et al.*<sup>95</sup> concluded that a natural enamel antagonist is preferable for the simulation of wear in the occlusal contact area and their study also revealed that there was no need to standardize the natural antagonist.

Many penetration studies involve "one point in time" and that is usually immediately after the material was placed and has had adequate time to set. Other studies have attempted to reproduce or simulate the condition of extended function by placing test materials in 100 per cent humidity for a period of time after placement in the cavity and then performing the dye tests. However, these circumstances do not replicate the clinical reality that marginal breakdown and loss of integrity may result from function over a period of time and at any one point in time whilst at 100 per cent humidity. Intracanal dressing changes or additional appointments may be frequent in clinical endodontics and currently there are no penetration studies that explore the possibility that this may influence the interim restoration.

Naoum and Chandler<sup>96</sup> recently reviewed the temporization of teeth undergoing root canal treatment. They recognized the need for temporary restorations in endodontics and that differing materials

are required depending on the length of time anticipated for temporization. They concluded that "further research is necessary to determine the effectiveness of temporary restorations in the conditions of the oral environment, especially with respect to leakage and functional demands". The study of Pane *et al.*<sup>81</sup> regarding the flexure of premolars with and without stainless steel bands suggests that it is likely that stainless steel bands will influence the amount of penetration associated with extensive interim restorations. This concept is worthy of investigation when considering load and the effect on the integrity of interim restorations.

## RECOMMENDATIONS

The literature does not contain any clear guidelines regarding which materials and techniques to use as interim restorations during endodontic treatment. In addition, there are no clear guidelines regarding materials and techniques for temporary restorations within endodontic access cavities that have been cut through interim restorations. Hence, the following guidelines are suggested as methods that suit most situations; they are based on clinical experience over many years rather than definitive research as such is lacking.

Interim restorations can generally be placed using a glass ionomer material and preferably one that has a different colour to the tooth (e.g., Ketac Silver – 3M ESPE, Seefeld, Germany), except when there are aesthetic considerations. The colour difference is recommended as this facilitates removal of the restoration prior to definitive restoration once the endodontic treatment has been completed. The colour contrast enables more tooth structure to be conserved as the material/tooth interface is easily seen.

The use of stainless steel bands is recommended in extensive cavities since they can help to reduce flexure of cusps as outlined above. However, perhaps the most important role of a band is to act as an aid to retention of the interim restoration since the band will have "extra coronal" contact with the tooth structure and hence will provide retention and resistance form in much the same manner as a crown does. As a general rule, if there are one or more cusps missing from a tooth, then a band should be placed – this particularly applies to premolar teeth. In many teeth, it may be possible to place an interim restoration without using a band and the restoration may be stable initially. However, once an access cavity has been cut through it, the interim restoration will be weakened and it may dislodge or develop marginal breakdown. The use of a band can avoid this and will thereby avoid the need to replace the interim restoration at subsequent visits.

If a band is used, then light curing of the restorative material will not be possible. Hence, a "chemical cure" material should be used (e.g., Ketac Silver). The inside fitting surface of the band should be lined with the material prior to cementation on the tooth, and then

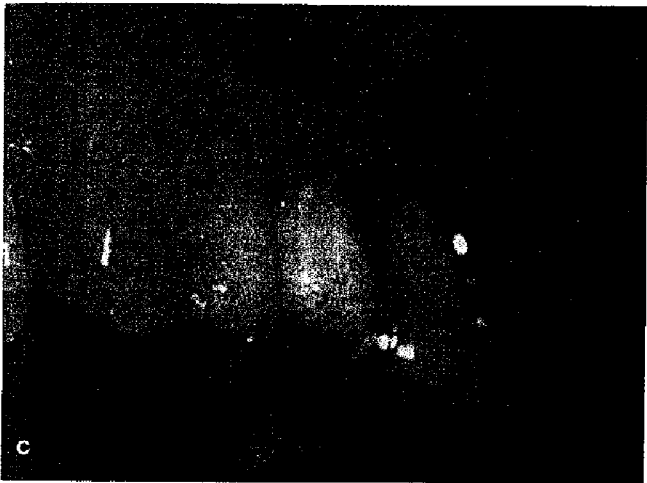
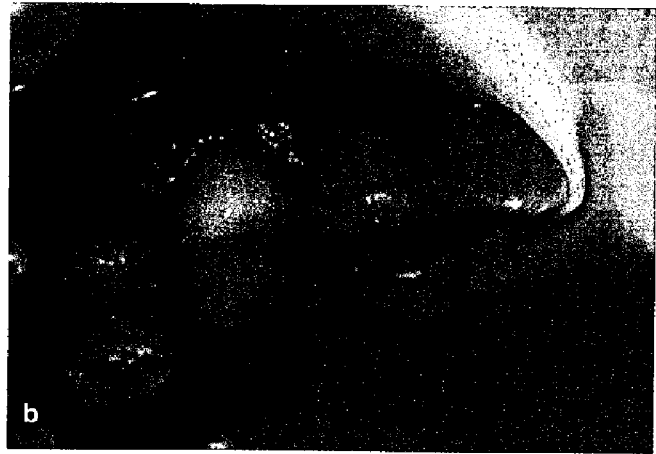
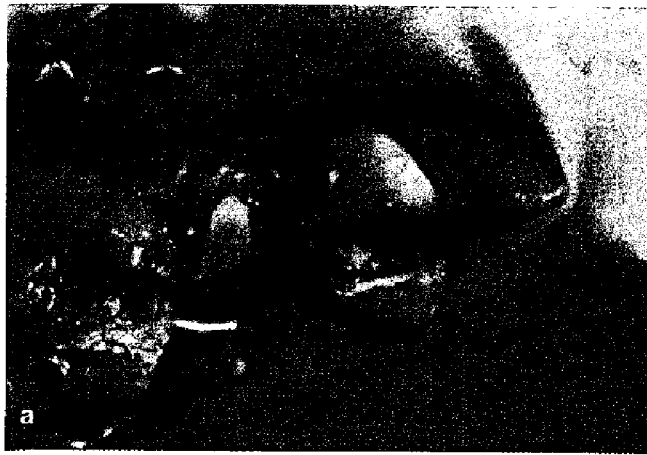
Fig 4. A clinical example of an upper second premolar tooth that requires an interim restoration to enable endodontic treatment to be continued. A rubber dam has been placed using the cuff technique. (a) The tooth is ready for an interim restoration to be placed after investigation, canal negotiation and medication, and the placement of cotton wool in the pulp chamber followed by a layer of Cavit. (b) The interim restoration has been placed using a stainless steel band and Ketac Fil. The buccal surface of the band has been veneered with the Ketac Fil to create an aesthetic interim restoration. (c) The rubber dam has been removed and the occlusion has been checked and adjusted. Final polishing has been completed. The GIC appears whiter than the adjacent teeth but it will more closely match their colour once its moisture content has stabilized.

the same material can be used to fill the cavity once the band has been seated. Figure 3 demonstrates the technique for placing a stainless steel band with two GIC materials.

When the tooth being treated is in an "aesthetic zone" (e.g., upper first premolar teeth), then the use of a band may not be ideal since the metal surface may be visible. However, this problem can be easily overcome by overlaying the buccal aspect of the band with a tooth-coloured chemically-cured glass ionomer material (e.g., Ketac Fil – 3M ESPE, Seefeld, Germany) in order to simulate the appearance of the buccal cusp. This technique is particularly useful when the tooth is missing the buccal cusp but can also be used when the palatal or lingual cusp is missing. In order to help retain the buccal veneer of glass ionomer, two or three small holes should be drilled through the buccal aspect of the band and the material should be allowed to flow into these holes to join with the underlying material (Figs 3 and 4).

Not all cases will require a stainless steel band to help retain the interim restoration (Fig 5). Such cases should have the interim restoration placed by using a suitable matrix band to ensure adequate fit and contour of the material. In all cases, both with and without bands, it is essential that the patient be able to clean around the tooth and restoration in a normal manner with tooth-brushing and flossing. Patients should be advised to do so and instructed on how to do it.

Anterior teeth that have had restorations removed will require different forms of interim restorations, according to how much tooth structure remains and

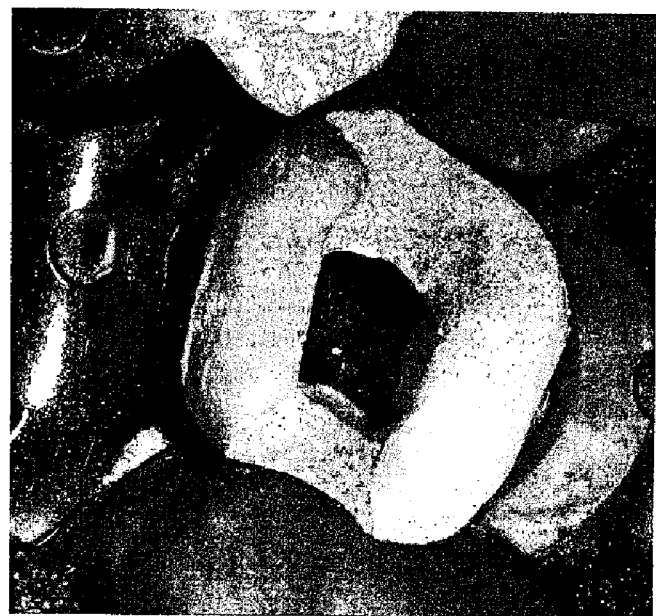


Fig 5. An example of a lower molar tooth that did not require a stainless steel band as part of the interim restoration as there was sufficient tooth structure remaining to retain the interim restoration without risking fracture or breakdown of the restoration and the tooth once an access cavity was cut through the interim restoration at the second appointment. In this case, Ketac Silver was placed using a matrix band. This photo shows the tooth at the second appointment following preparation of the access cavity.

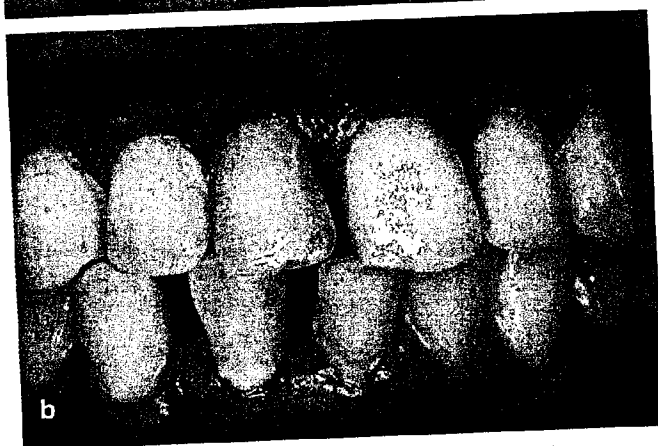
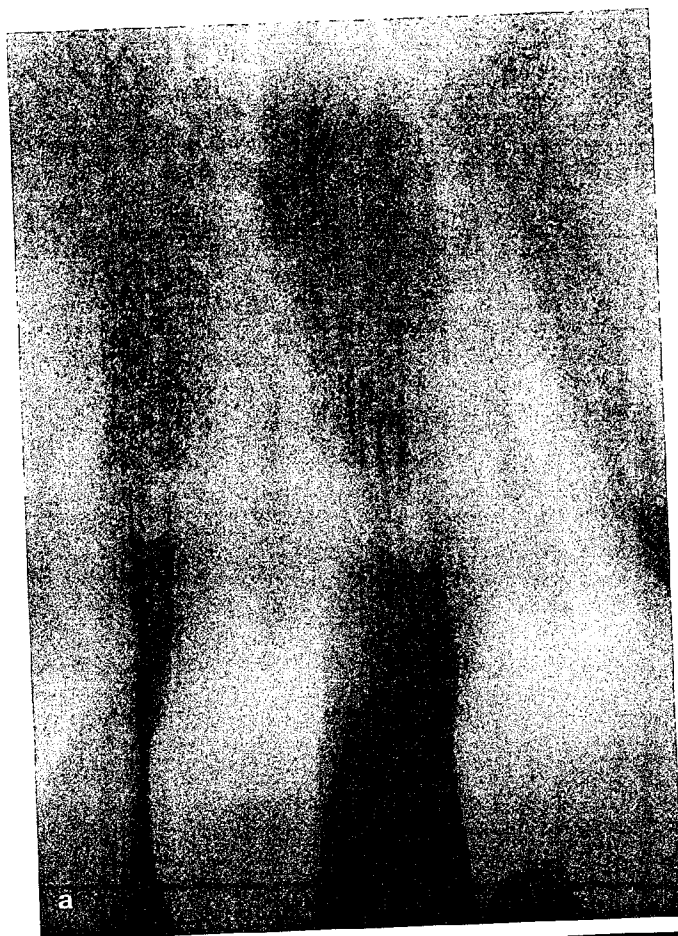
Fig 6. An upper right central incisor tooth that had acute irreversible pulpitis as a result of an extensive mesial crown:root fracture. (a) The pre-operative radiograph shows the extent of the fracture. (b) The tooth had a Ketac Fil interim restoration placed and this photo shows the interim restoration at a three-month review examination. There is slight discolouration of the material but it has provided the patient with an acceptable interim restoration whilst endodontic treatment was performed and until the tooth could be restored more definitively.

this will be determined by the extent of the previous restoration as well as by the amount of any caries or cracks that have been removed during the investigation of the tooth. The simplest option for teeth that have not had extensive loss of tooth structure is to use simple tooth-coloured glass ionomer restorations (e.g., Ketac Fil) placed with celluloid strips or other forms of matrix band (Figs 6 and 7).

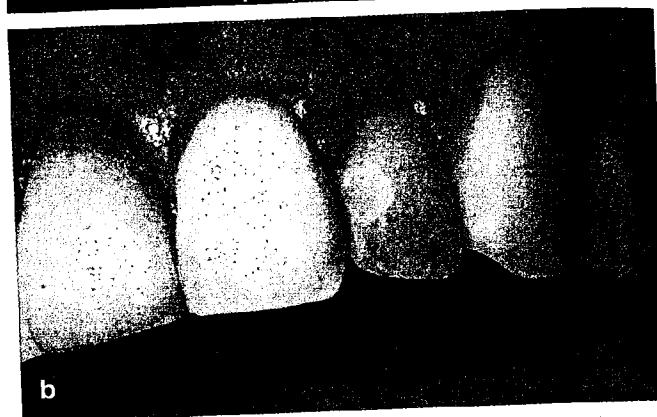
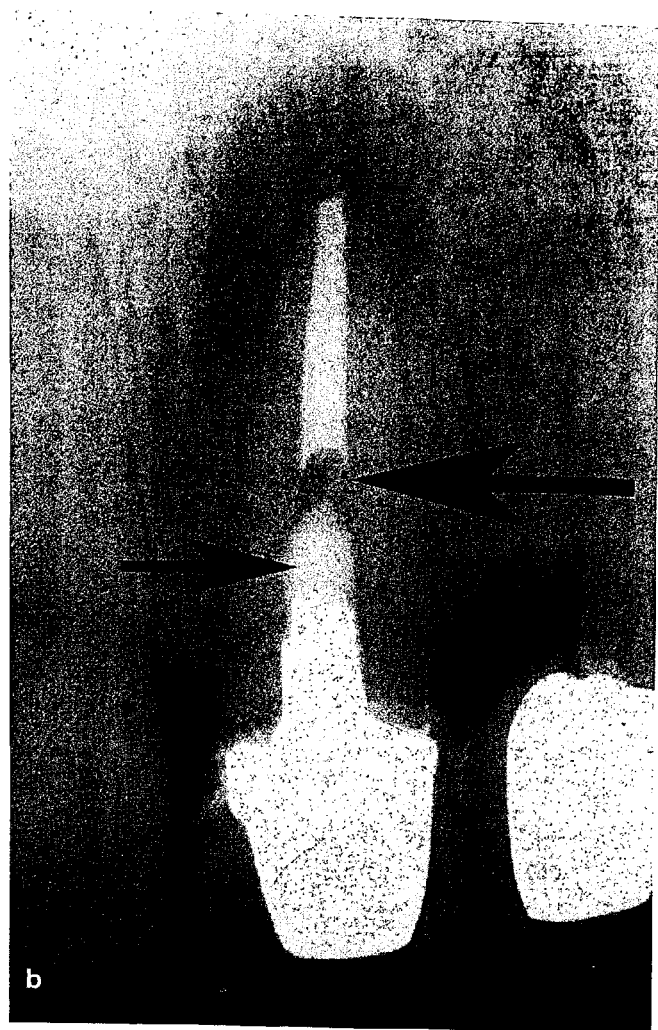
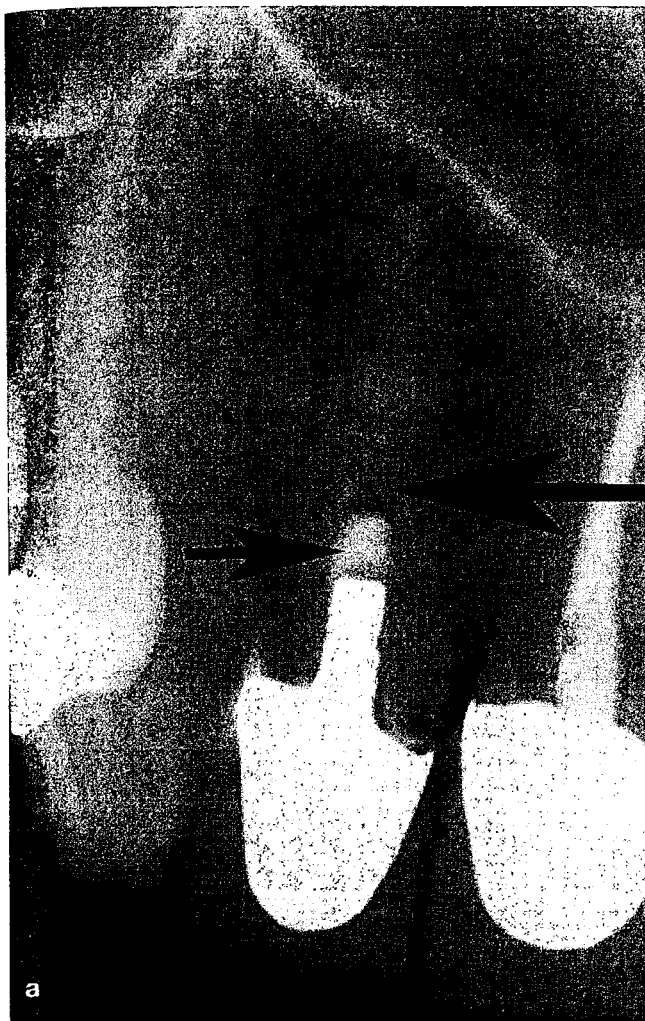

Fig 7. The upper left lateral incisor had a pulpless, infected root canal system with chronic apical periodontitis as a result of breakdown of the mesial composite resin restoration that had been placed approximately 3 years earlier. Hence, this tooth required endodontic treatment. (a) The pre-operative clinical view of the tooth shows staining of the margins of the mesial composite resin restoration. (b) The composite resin was removed as part of the initial investigation of the tooth and then an interim Ketac Fil restoration was placed. Once the endodontic treatment was completed, the tooth was internally bleached. This photograph shows the tooth with the interim restoration when the bleaching was completed, which was four months after the endodontic treatment was commenced.

Posterior teeth that have had crowns removed can have interim restorations placed in the same manner as outlined above using stainless steel bands and a GIC material. However, an anterior tooth that has had a previous crown removed, or if there has been extensive loss of tooth structure, is likely to require an interim crown due to aesthetic reasons. Such a restoration can be constructed from any of the cold-cure acrylic materials that are used for crown and bridgework. Ideally, a strong and reliable cement should be used, such as IRM or a zinc phosphate cement. Most of the "temporary" cements used for routine crown and bridgework are unreliable over long periods of time and therefore should be avoided. If an interim post is required to help with retention, then some cotton wool and a layer of Cavit should be placed at the base of the post hole prior to cementing the interim post/crown (Fig 8). This approach provides an extra layer of material between the oral cavity and the root canal system and therefore should help to prevent bacterial penetration, although there is no scientific evidence to support (or refute) this statement at present.



**Fig 8.** Two examples of upper anterior teeth that had the existing crowns and posts/cores removed to enable endodontic re-treatment to be performed. In both examples, the existing posts and crowns were used to construct interim restorations by shortening the posts and lining the restorations with a cold-cure acrylic resin material. The radiographs demonstrate how cotton wool (large arrows) and Cavit (smaller arrows) have been placed deep within the post holes to act as secondary barriers/seals under the interim restorations and as a precaution in case the interim post/crown dislodges. (a) The upper right lateral incisor tooth needed endodontic re-treatment because it had an infected root canal system and chronic apical periodontitis. In this case, the interim post/crown was cemented on the tooth with a "tacky" mix of IRM. (b) The upper left central incisor tooth needed endodontic re-treatment because it had an infected root canal system and a secondary acute apical abscess. In this case, zinc phosphate cement was used to cement the interim post/crown.

Other possible interim restorations for anterior teeth that have had extensive loss of tooth structure and would otherwise need an interim post/crown include an interim acrylic partial denture (Figs 9a and 9b), an interim overlay composite bridge bonded to the adjacent teeth, a provisional bridge if the adjacent teeth require crowns (Fig 9c), and possibly other techniques developed by individual dentists. The important thing to consider when treating these cases is to cover all exposed dentine so there are no open dentinal tubules through which bacteria could enter the tooth. Once again, a glass ionomer material with contrasting colour to the tooth is recommended. However, these techniques are usually more difficult to perform, more time consuming and more expensive than using interim crowns in the manner described above. In addition, most patients find temporary dentures cumbersome and uncomfortable to wear whereas an interim crown is unobtrusive and easy to maintain.

As discussed above, Cavit has been shown to perform reasonably well as a barrier to fluid penetration as long as it is not loaded in occlusal function. Hence, this property can be used to advantage when placing interim restorations as well as when placing temporary restorations. Prior to placing the interim restoration, some cotton wool and Cavit should be placed in the pulp chamber (Fig 3a) and then the interim restoration can be built up over this material (Figs 3e and 3f). The main purposes of using Cavit in this situation are to prevent the interim material from going into the pulp chamber and root canals, and to facilitate easy access back into the canals at the next appointment.

Although Cavit has been shown to prevent fluid penetration when not loaded, no studies have demonstrated that it prevents bacterial penetration, either with or without loading. However, the work of Liberman *et al.*<sup>92</sup> suggests that it is unlikely to provide a



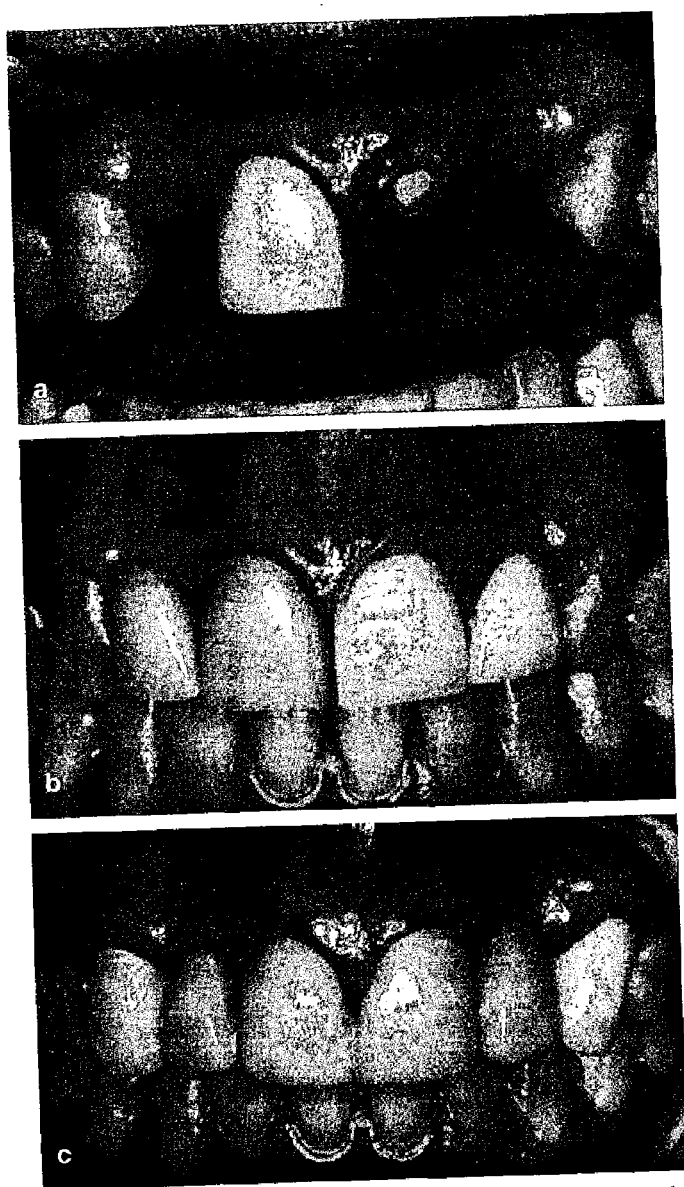


Fig 9. Example of an upper left central incisor tooth that required endodontic re-treatment following removal of the crown and post/core. Different interim restorations have been utilized at different stages of the patients overall treatment. (a) The tooth following investigation by removal of the crown, post/core, caries and previous root filling. An intracanal medicament has been placed, followed by some cotton wool and a layer of Cavit. The tooth is now ready to have a "dome" or cover of Ketac Silver placed over the exposed dentine in order to close all the dentinal tubules and to help prevent any further ingress of bacteria in between treatment appointments. (b) A "denture tooth" has been added to the patient's expositing acrylic-based upper partial denture. The denture tooth has been added so that it overlays the root and covers the Ketac Silver "dome" whilst also providing a stable, aesthetic interim restoration for the patient. (c) After the endodontic treatment had been completed and a new cast post/core had been cemented into the tooth, a provisional acrylic bridge was constructed. This type of provisional bridge could also have been used during the endodontic treatment as an interim restoration provided the root had still been covered by Ketac Silver (or other similar material) but it is less convenient as it needs to be removed at each endodontic appointment and it is more expensive to construct in the laboratory.

seal against bacteria when loaded since the loading led to rapid and complete fluid penetration which indicates a lack of marginal integrity. Cavit is also quite a soluble and weak material, which wears away relatively rapidly

when in function in the mouth. Hence, Cavit would appear to be less than ideal as a temporary material to be used alone in an endodontic access cavity that has been cut through an interim restoration. An alternative material to consider is a zinc oxide-eugenol material, such as IRM, since this material has been shown to prevent bacterial penetration into tooth cavities.<sup>27,28,97,98</sup> IRM is a relatively strong and insoluble material that does not wear rapidly. However, IRM does not prevent fluid penetration very well, especially under occlusal load. Hence, a combination of these two materials seems likely to overcome the disadvantages of each whilst also utilizing the advantages of them both. This technique is commonly referred to as a "double seal" technique.

The "double seal" technique involves placing Cavit as the deeper layer material inside the pulp chamber and access cavity. The IRM is then used as the outer layer which is exposed to loading and the oral cavity. This double layer functions in several ways:

- the outer layer of IRM is an antibacterial agent,
- the IRM is less soluble, wears less and is stronger,
- the inner layer of Cavit prevents any moisture (i.e., saliva) from reaching the root canal system if it has been able to penetrate through the IRM margins.

The white colour of the IRM is readily visible (Fig 2d) when the clinician needs to remove it at a subsequent visit. IRM is also a cheap material that is easily and quickly mixed and placed in the tooth. It sets quickly and therefore there is no "waiting time" after placement before the rubber dam can be removed. Some clinicians use a glass ionomer as the outer layer over the Cavit but this is a more expensive and slower technique, with no research available to demonstrate whether these materials are effective at achieving a seal at the interface between the old and the newly-placed GIC material. Hence, IRM is recommended as the outer layer material.

The above techniques are simple and adaptable to almost every clinical situation. These restorations can last a long time (Fig 1b) and they also allow the placement of rubber dam at subsequent visits although it is usually preferable to use the "cuff technique" (Figs 2 and 4) by placing the clamp on another tooth distal to the one being treated in order to minimize the chances of disturbing the interim restoration. The above techniques use the philosophies of "place the interim restoration once only" and "place it well" so it will not dislodge, break down or cause any other problems during the endodontic treatment. If these concepts are followed, then the endodontic treatment will be simplified and less likely to have inter-appointment problems such as loose or lost restorations, and/or contamination of the root canal system, all of which necessitate the re-commencement of the root canal disinfection procedures.

If the above techniques cannot be easily adapted to a particular clinical situation, then it is highly unlikely that an adequate interim restoration can be placed at



all. In such cases, the operator should reconsider whether the tooth is suitable for endodontic treatment and a subsequent restoration since the most likely reason that an interim restoration cannot be placed and retained is the lack of adequate tooth structure. Hence, the tooth is also unlikely to be restorable with any form of definitive restoration which contra-indicates the tooth from having endodontic treatment.

## CONCLUSIONS

There is a lack of literature investigating the bacterial penetration of interim restorations placed as part of endodontic treatment. There is also little evidence regarding the effects of cutting access cavities through these interim restorations. Of the studies reviewed, none have involved adequate representative loading of the restorations or consideration of the material variables involved. Furthermore, many of the fluid penetration studies have attempted to quantify so-called (but inappropriately termed) "leakage" and have not utilized methods that are proven to represent a true bacterial penetration model. All of the above are worthy of investigation as they are representing the everyday clinical practice. The presence of bacteria within the root canal system is the most common cause of ongoing periapical disease following endodontic treatment and therefore all efforts must be made to remove all bacteria and prevent further ingress into the tooth during and after endodontic treatment. Hence, the role of interim and temporary restorations should not be undervalued and more emphasis should be placed upon their importance within endodontic treatment protocols.

## REFERENCES

1. Kakehashi S, Stanley H, Fitzgerald R. The effects of surgical exposures of dental pulps in germ-free and conventional laboratory rats. *Oral Surg Oral Med Oral Pathol* 1965;20:340-349.
2. Möller Å. Microbiological examination of root canals and periapical tissues of human teeth. *Methodological studies. Odont Tidskr* 1966;74:Suppl:1-380.
3. Sundqvist G. Bacteriological studies of necrotic dental pulps. Umeå University Odontological Dissertations No. 7. Umeå: Umeå University, Sweden; 1976.
4. Möller Å, Fabricius L, Dahlen G, Ohman A, Heyden G. Influence on periapical tissues of indigenous oral bacteria and necrotic pulp tissue in monkeys. *Scand J Dent Res* 1981;89:475-484.
5. Bergenholtz G. Micro-organisms from necrotic pulp of traumatized teeth. *Odont Rev* 1974;25:347-358.
6. Fabricius L, Dahlen G, Holm S, Möller Å. Influence of combinations of oral bacteria on periapical tissues of monkeys. *Scand J Dent Res* 1982;90:200-206.
7. Sundqvist G, Eckerbom M, Larsson A, Sjögren U. Capacity of anaerobic bacteria from necrotic dental pulps to induce purulent infections. *Infect Immunol* 1979;25:685-693.
8. Seltzer S, Farber P. Microbiologic factors in endodontology. *Oral Surg Oral Med Oral Pathol Oral Radiol Endod* 1994;78:634-645.
9. Roulet J. Marginal integrity: clinical significance. *J Dent* 1994;22:Suppl:S9-12.
10. Zimet P. Preservation of the roots – management and prevention protocols for cracked tooth syndrome. *Ann R Australas Coll Dent Surg* 2000;15:319-324.
11. Young W. The oral medicine of tooth wear. *Aust Dent J* 2001;46:236-250.
12. Tronstad L, Langeland K. Effect of attrition on subjacent dentin and pulp. *J Dent Res* 1971;50:17-30.
13. Murray P, Hafez A, Smith A, Cox C. Bacterial microleakage and pulp inflammation associated with various restorative materials. *Dent Mat* 2002;18:470-478.
14. Abbott P. Assessing restored teeth with pulp and periapical diseases for the presence of cracks, caries and marginal breakdown. *Aust Dent J* 2004;49:33-39.
15. Kane A, Cisse D, Faye D, Toure B, Sarr M. Importance of the number of treatment sessions in the success of root canal therapy. *Dakar Med* 1999;44:109-113.
16. Ahmed M, Elseed A, Ibrahim Y. Root canal treatment in general practice in Sudan. *Int Endod J* 2000;33:316-319.
17. Siqueira JJ. Microbial causes of endodontic flare-ups. *Int Endod J* 2003;36:453-463.
18. Negm M. Intracanal use of a corticosteroid-antibiotic compound for the management of post-treatment endodontic pain. *Oral Surg Oral Med Oral Pathol Oral Radiol Endod* 2001;92:435-439.
19. Trope M, Delano E, Orstavik D. Endodontic treatment of teeth with apical periodontitis: single vs. multi-visit treatment. *J Endod* 1999;25:345-350.
20. Sjögren U, Sundqvist G. Bacteriologic evaluation of ultrasonic root canal instrumentation. *Oral Surg Oral Med Oral Pathol Oral Radiol Endod* 1987;63:366-370.
21. Matusow R. The flare-up phenomenon in endodontics: a clinical perspective and review. *Oral Surg Oral Med Oral Pathol Oral Radiol Endod* 1990;70:345-348.
22. Nair P, Henry S, Cano V, Vera J. Microbial status of apical root canal system of human mandibular first molars with primary apical periodontitis after "one-visit" endodontic treatment. *Oral Surg Oral Med Oral Pathol Oral Radiol Endod* 2005;99:231-252.
23. Joy E, Barber J. Psychological, physiological, and pharmacological management of pain. *Dent Clin Nth Am* 1977;21:577-593.
24. Murtomaa H, Haavio-Mannila E, Kandolin I. Burnout and its causes in Finnish dentists. *Comm Dent Oral Epidemiol* 1990;18:208-212.
25. Siren E, Haapasalo M, Ranta K, Salmi P, Kerosuo E. Microbiological findings and clinical treatment procedures in endodontic cases selected for microbiological investigation. *Int Endod J* 1997;30:91-95.
26. <http://dictionary.oed.com/cgi/entry/00130970?single=1&queryword=leakage>. Oxford English Dictionary. 2nd edn. 1989. Accessed 4 October 2004.
27. Brännstrom M, Nyborg H. The presence of bacteria in cavities filled with silicate cement and composite resin materials. *Swed Dent J* 1971;64:149-155.
28. Brännstrom M, Johnson G. Effects of various conditioners and cleaning agents on prepared dentine surfaces. *J Prosthet Dent* 1974;31:422-430.
29. Melton D, Cobb S, Krell K. A comparison of two temporary restorations: light-cured resin versus a self-polymerizing temporary restoration. *Oral Surg Oral Med Oral Pathol* 1990;70:221-533.
30. Delivanis P, Snowden R, Doyle R. Localization of blood-borne bacteria in instrumented unfilled root canals. *Oral Surg Oral Med Oral Pathol* 1981;52:430-432.
31. Bamzahi M, Shi X, Angmar-Mansson B. Secondary caries detection by DIAGNOdent and radiography: a comparative in vitro study. *Acta Odontol Scand* 2004;62:61-64.
32. Thomas G. The diagnosis and treatment of the cracked tooth syndrome. *Aust Prosth J* 1989;3:63-67.
33. Culjat M, Singh R, Brown E, Neurgaonkar R, Yoon D, White S. Ultrasound crack detection in a simulated human tooth. *Dentomaxillofac Radiol* 2005;34:80-85.

34. Santini A. The diagnosis, classification and treatment of acute pulpal pain by UK general dental practitioners: results of a survey. *Prim Dent Care* 1996;3:24-27.
35. Walton R. Access preparation and length determination. In: Walton R, Torabinejad M, eds. *Principles and Practice of Endodontics*. 2nd edn. Philadelphia: W.B. Saunders Company, 1996:180-200.
36. Alavi A, Kianimanesh N. Microleakage of direct and indirect composite restorations with three dentin bonding agents. *Oper Dent* 2002;27:19-24.
37. Ziskind D, Elbaz B, Hirschfeld Z, Rosen L. Amalgam alternatives-microleakage evaluation of clinical procedures. Part II: direct/indirect composite inlay systems. *J Oral Rehab* 1998;25:502-506.
38. Goldman M, Laasonthorn P, White R. Microleakage – full crowns and the dental pulp. *J Endod* 1992;18:473-475.
39. Turner J, Anderson R, Pashley D, Pantera EJ. Microleakage of temporary endodontic restorations in teeth restored with amalgam. *J Endod* 1990;16:1-4.
40. Gutmann J, Tidwell E. Restoring endodontically treated teeth. *Tex Dent J* 1997;114:14-23.
41. Smith C, Schuman N. Restoration of endodontically treated teeth: a guide for the restorative dentist. *Quintess Int* 1997;28:457-462.
42. McKerracher P. Rational restoration of endodontically treated teeth. I. Principles, techniques, and materials. *Aust Dent J* 1981;26:205-208.
43. Fagin M. Restoration of endodontically treated teeth. *Int J Perio Rest Dent* 1981;1:8-29.
44. Sadan A, Elliot R, Raigrodski A. Treatment planning extensively broken-down mandibular molars for post-and-core fabrication. *Quintess Int* 1998;29:351-355.
45. McDonald A, Setchell D. Developing a tooth restorability index. *Dent Update*. 2005;32:343-348.
46. Saunders W. Restoration of the root filled tooth. In: Ørstavik D, Pitt Ford T, eds. *Essential Endodontology – Prevention and Treatment of Apical Periodontitis*. Oxford: Blackwell Science Ltd, 1998:331-366.
47. Anusavice K. *Phillips' Science of Dental Materials*. 10th edn. Philadelphia: W.B. Saunders Company, 1996.
48. Vail M, Guba P. Apical healing of an endodontically treated tooth with a temporary restoration. *J Endod* 2002;28:724-726.
49. Sturdevant C, Roberson T, Heymann H, Sturdevant J. *The Art and Science of Operative Dentistry*. 3rd edn. St Louis: Mosby, 1995.
50. Banchs F, Trope M. Revascularization of immature permanent teeth with apical periodontitis: new treatment protocol? *J Endod* 2004;30:196-200.
51. Pai S, Yang S, Sue W, Chueh L, Rivera E. Microleakage between endodontic temporary restorative materials placed at different times. *J Endod* 1999;25:453-456.
52. Hagemeyer M, Cooley R, Hicks J. Microleakage of five temporary endodontic restorative materials. *J Esthet Dent* 1990;2:166-169.
53. Blaney T, Peters D, Setterstrom J, Bernier W. Marginal sealing quality of IRM and Cavit as assessed by microbiol penetration. *J Endod* 1981;7:453-457.
54. Wu M, Wesselink P. Endodontic leakage studies reconsidered. Part I. Methodology, application and relevance. *Int Endod J* 1993;26:37-43.
55. Wu M, De Gee A, Wesselink P. Fluid transport and dye penetration along root canal fillings. *Int Endod J* 1994;27:233-238.
56. Wimonchit S, Timpawat S, Vongsavan N. A comparison of techniques for assessment of coronal dye leakage. *J Endod* 2002;28:1-4.
57. Goldman M, Simmonds S, Rush R. The usefulness of dye-penetration studies re-examined. *Oral Surg Oral Med Oral Pathol* 1989;67:327-332.
58. Barthel C, Moshonov J, Shuping G, Ørstavik D. Bacterial leakage versus dye leakage in obturated root canals. *Int Endod J* 1999;32:370-375.
59. Spångberg L, Acierno T, Yongbum Cha B. Influence of entrapped air on the accuracy of leakage studies using dye penetration methods. *J Endod* 1989;15:548-551.
60. Oliver C, Abbott P. Entrapped air and its effects on dye penetration of voids. *Endod Dent Traumatol* 1991;7:135-138.
61. Kontakiotis E, Georgopoulou M, Morfis A. Dye penetration in dry and water-filled gaps along root fillings. *Int Endod J* 2001;34:133-136.
62. Camps J, Pashley D. Reliability of the dye penetration studies. *J Endod* 2003;29:592-594.
63. Kazemi R, Safavi K, Spångberg L. Assessment of marginal stability and permeability of an interim restorative endodontic material. *Oral Surg Oral Med Oral Pathol Oral Radiol Endod* 1994;78:788-796.
64. Zmener O, Banegas G, Pameijer C. Coronal microleakage of three temporary restorative materials: an in vitro study. *J Endod* 2004;30:582-584.
65. Barkhordar R, Stark M. Sealing ability of intermediate restorations and cavity design used in endodontics. *Oral Surg Oral Med Oral Pathol* 1990;69:99-101.
66. Lee Y, Yang S, Hwang Y, Chueh L, Chung K. Microleakage of endodontic temporary restorative materials. *J Endod* 1993;19:516-520.
67. Noguera A, McDonald N. Comparative in vitro coronal microleakage study of new endodontic restorative materials. *J Endod* 1990;16:523-527.
68. Hansen S, Montgomery S. Effect of restoration thickness on the sealing ability of TERM. *J Endod* 1993;19:448-452.
69. Spratt D. Significance of bacterial identification by molecular biology methods. *Endod Topics* 2004;9:5-14.
70. Olsen I, Dahlén G. Salient virulence factors in anaerobic bacteria, with emphasis on their importance in endodontic infections. *Endod Topics* 2004;9:15-26.
71. Svensäter G, Bergenholtz G. Biofilms in endodontic infections. *Endod Topics* 2004;9:27-36.
72. Handelsman I. Endodontic access cavity: concepts and design. *Endod Report* 1989;8-11.
73. Druttman A. Apical problems – coronal solutions: how changes in access cavity design can prevent and overcome problems with curved canals. *Refuat Hapeh Vehashinayim* 2004;21:7-16.
74. Webber R, del Rio C, Brady J, Seagal R. Sealing quality of a temporary filling material. *Oral Surg* 1978;46:123-129.
75. Deveaux E, Hildebert P, Neut C, Boniface B, Romond C. Bacterial microleakage of Cavit, IRM, and TERM. *Oral Surg Oral Med Oral Pathol Oral Radiol Endod* 1992;74:634-643.
76. Anderson R, Powell B, Pashley D. Microleakage of temporary restorations in complex endodontic access preparations. *J Endod* 1989;15:526-529.
77. Ehrmann E. The use of stainless steel bands in posterior endodontics. *Aust Dent J* 1968;13:418-421.
78. Ehrmann E, Tyas M. Cracked tooth syndrome: diagnosis, treatment and correlation between symptoms and post-extraction findings. *Aust Dent J* 1990;35:105-112.
79. Liu H, Sidhu S. Cracked teeth – treatment rationale and case management: case reports. *Quintess Int* 1995;26:485-492.
80. Abbott P. *Endodontics and Dental Traumatology – An Overview of Modern Endodontics*. Teaching Manual. Perth, Australia: The University of Western Australia; 1999:47-49.
81. Pane E, Palamara J, Messer H. Stainless steel bands in endodontics: effects on cuspal flexure and fracture resistance. *Int Endod J* 2002;35:467-471.
82. Huser M, Baehni P, Lang R. Effects of orthodontic bands on microbiologic and clinical parameters. *Am J Orthod Dentofacial Orthop* 1990;97:213-218.

83. Sapone J, Lorencki S. An endodontic-prosthodontic approach to internal tooth reinforcement. *J Prosthet Dent* 1981;45:164-174.
84. Mayer T, Eickholz P. Microleakage of temporary restorations after thermocycling and mechanical loading. *J Endod* 1997;23:320-322.
85. Balto H. An assessment of microbial coronal leakage of temporary filling materials in endodontically treated teeth. *J Endod* 2002;28:762-764.
86. Jacquot B, Panighi M, Steinmetz P, G'Sell C. Evaluation of temporary restorations' microleakage by means of electrochemical impedance measurements. *J Endod* 1996;22:586-589.
87. Jacquot B, Panighi M, Steinmetz P, G'Sell C. Microleakage of Cavit, Cavit W, Cavit G and IRM by impedance spectroscopy. *Int Endod J* 1996;29:256-261.
88. Rafeek R, Smith W, Lalla A. Assessment of coronal microleakage of three materials used in endodontically treated teeth. *Eur J Prosthodont Restor Dent* 2004;12:39-43.
89. Uctasli M, Tinaz A. Microleakage of different types of temporary restorative materials used in endodontics. *J Oral Sci* 2000;42:63-67.
90. Roghanizad N, Jones J. Evaluation of coronal microleakage after endodontic treatment. *J Endod* 1996;22:471-473.
91. Rutledge R, Montgomery S. Effect of intracanal medicaments on the sealing ability of TERM. *J Endod* 1990;16:260-264.
92. Liberman R, Ben-Amar A, Frayberg E, Abramovitz I, Metzger Z. Effect of repeated vertical loads on microleakage of IRM and calcium sulfate-based temporary fillings. *J Endod* 2001;27:724-729.
93. Scherman L, Nebot D. Comparative study of the seal and porosity of provisional coronal filling materials in endodontics. *Rev Fran Endod* 1989;8:17-23.
94. Hakimeh S, Vaidyanathan J, Houpt M, Vaidyanathan T, Von Hagen S. Microleakage of compomer class V restorations: effect of load cycling, thermal cycling, and cavity shape differences. *J Prosthet Dent* 2000;83:194-203.
95. Krejci I, Albert P, Lutz F. The influence of antagonist standardization on wear. *J Dent Res* 1999;78:713-719.
96. Naoum H, Chandler N. Temporization for endodontics. *Int Endod J* 2002;35:964-978.
97. Hume WR. An analysis of the release and the diffusion through dentin of eugenol from zinc oxide-eugenol mixtures. *J Dent Res* 1984;63:881-884.
98. Hume WR. The pharmacologic and toxicological properties of zinc oxide-eugenol. *J Am Dent Assoc* 1986;113:789-791.

*Address for correspondence/reprints:*

Professor Paul Abbott  
 School of Dentistry  
 The University of Western Australia  
 17 Monash Ave  
 Nedlands, Western Australia 6009  
 Email: paul.v.abbott@uwa.edu.au

Reproduced with permission of the copyright owner. Further reproduction prohibited without permission.